

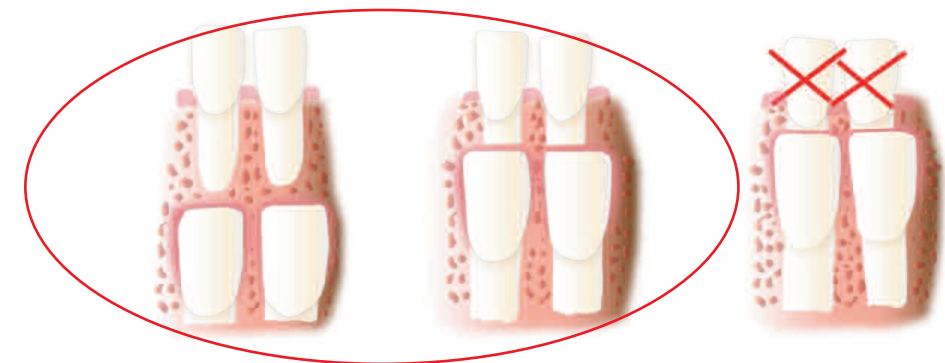StemSave's Tooth Eligibility Criteria

A healthy pulp contains viable stem cells.

For a pulp to be considered healthy, the tooth must have an intact blood supply, be free of infection, deep caries and other pathologies. Stem cells are not concentrated within any particular area of a healthy pulp, but are diffusely spread throughout the cellular zone adjacent to the nerve and blood vessels within the pulp. Specific criteria must be met in order for a tooth to be eligible for stem cell recovery. StemSave has broken this down into three distinct tooth groups in which patients have the opportunity to recover their stem cells. It is best to recover stem cells when a patient is young and healthy and the stem cells are at their most proliferative. Stem cells can also be recovered from the permanent teeth of middle-aged individuals. Benefits are realized at this age when compared to current life expectancy statistics, coupled with the almost certain need for their use in future regenerative therapies.

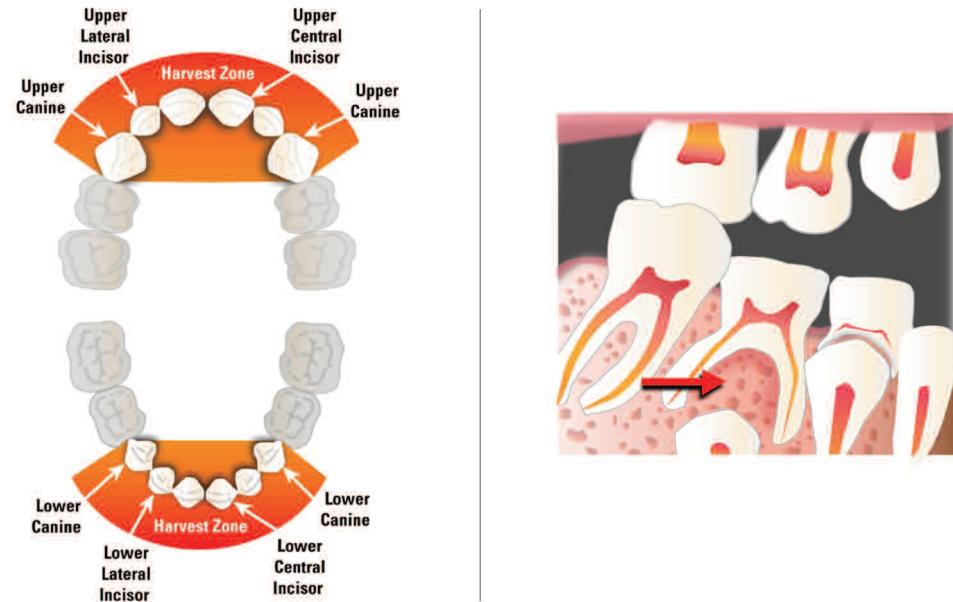
Deciduous Teeth: The healthy pulps of deciduous teeth are a rich source of viable stem cells. Scientific data supports that stem cells isolated from healthy pulp of deciduous teeth are highly proliferative, even when the pulp is recovered in small quantities. Certain factors will determine whether viable stem cells can be recovered from deciduous teeth.

- The ideal deciduous tooth for stem cell recovery is a canine or incisor that has just started to loosen, has more than a third of the root structure left intact, and is **not** extracted for reasons such as infection or associations with pathology.

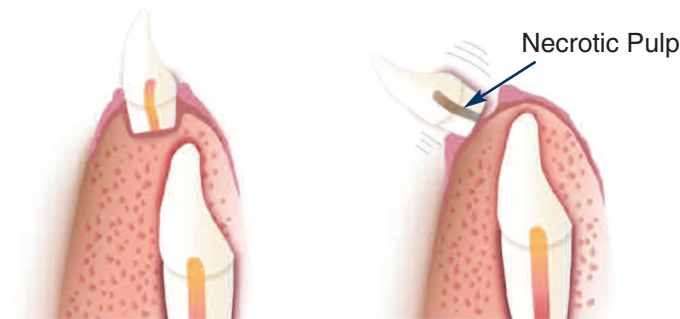


- Supernumerary or mesodens are another ideal source for dental stem cells. In most cases when these teeth are removed, they still have a complete root, intact blood supply and healthy pulp.

- **Harvest Zone:** The harvest zone for stem cells is from the deciduous canine to canine. Deciduous molars may have their pulp chambers obliterated by the erupting permanent bicuspid by the time they become loose. In most cases, the remaining pulpal tissue may not be adequate for dental stem cell recovery. Over-retained molars and molars extracted for orthodontic reasons may also be considered.

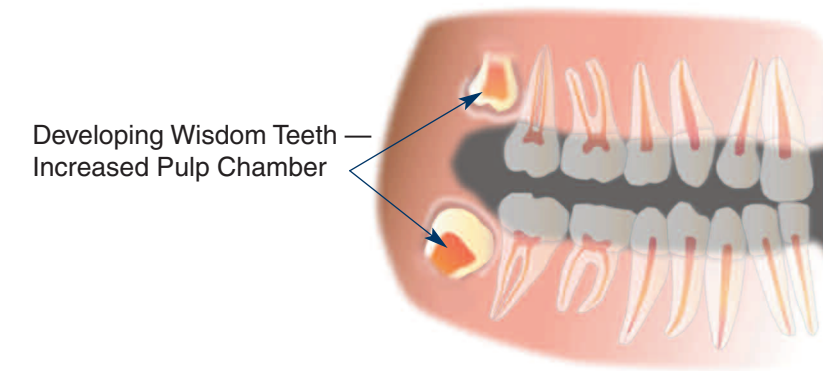


- The pulps of naturally exfoliated teeth or teeth that have fallen out on their own are most likely necrotic, as they have been separated from their blood supply. A patient bringing a tooth in hand to the office is not a good candidate for recovery.
- An excessively loose tooth or one that is “hanging on by a thread” is not a candidate for stem cell recovery. Even though the tooth is still attached to gingiva, the pulp most likely is necrotic.



Wisdom Teeth: The healthy pulp from wisdom teeth is another excellent source for viable stem cells. Whole or sectioned portions of third molars containing healthy pulp can be recovered at the time of their removal. When an impacted third molar needs to be sectioned for removal, the pulp is often exposed.

- Developing third molars have a larger volume of pulpal tissue than teeth that are mature with their roots completely formed.



- It is best to recover these teeth during the developmental stage (between 16-20 years of age), when the stem cells are very active in the formation of the root and supporting root structures.
- Third molars with healthy pulp can also be recovered later in life and are always considered a source for viable stem cells.

Permanent teeth: All permanent teeth with healthy pulp are potential sources of stem cells.

- Bicuspid needing to be removed for orthodontic indications are an example of this.
- Permanent teeth to avoid include: endodontically-treated or nonviable teeth, teeth with active infections, teeth with severe periodontal disease and excessive mobility, teeth with deep caries or large restorations, and teeth with sclerosing or calcified pulp chambers.
- Age is important. The stem cells from within the pulp become less proliferative as individuals age, so it is best to recover stem cells at the earliest opportunity.



Healthy Pulp Molar of 18 year old

Sclerosed Pulp Molar of 60 year old